



PATIENT

Jack Miyamoto

SPECIES

Feline

BREED

DSH

SEX

Male Neutered

AGE

4.6.14

WEIGHT

9.2lbs

INTERPRETED BY

Maggie Machen Lamy,
DVM, DACVIM
(Cardiology)

HOSPITAL NAME

Bel Air Veterinary
Hospital

REFERRING VET

Dr. Schmidt

INVOICE

28535

DATE

1.24.23

PRESENTING CLINICAL SIGNS

History: Recheck echo – h/o Hypertrophic Obstructive Cardiomyopathy. Weight gain of 1lb- suspect fluid.

-Radiographs results: Biventricular effusion

-Current medications: Atenolol 25mg -1/2-tab PO SID since 2019, Furosemide 20mg- 1/2 tab PO BID started 1/7/2023

-Sedation used: Not required to complete full diagnostic ultrasound.

-Pertinent previous ultrasound results (4/2017 MML): Mild LVH, mild SAM, mild MR, no LAE.

-STAT: Declined.

-Imaging performed by: Stephanie Warga RDCS, RVT.

ECHOCARDIOGRAM FINDINGS

2D, m-mode, color flow and doppler imaging is available. The left ventricular wall is asymmetric with a borderline septal thickening and moderate free wall hypertrophy. The LV chamber is normal with depressed myocardial function. There is a diffusely hyperechoic endocardium consistent with fibrosis. The papillary muscles are mildly hypertrophied and remodeled. The left atrium is severely dilated and bulbous in appearance. Subtle spontaneous contrast (smoke) visualized. The right atrium is moderately dilated. The mitral valve is mildly thickened; mild central MR due to annular stretch. Mild to moderate central TR due to annular stretch. Blood flow through both the LVOT and RVOT are decreased in velocity. Scant pericardial effusion seen. Pockets of pleural effusion.

CARDIAC CHART

FELINE CARDIAC PARAMETERS	BODY WEIGHT (kg)	HR (BPM)	IVSd (cm) (Moise, Pipers)	LVIDd (cm) (Moise, Pipers)	LWVd (cm) (Moise, Pipers)	FS (%)	EF (%)
NORMAL PARAMETER	-----	150-240	3.5-0.55	<2 (mean 1.5)	3.5-0.55	35-67	80-100
PATIENT	4.2	NM	0.6	1.3	0.7	31	63
FELINE CARDIAC PARAMETERS	LA/AO (Boon)	LA/AO HEART BASE (Swe) (Abbott)	LA 2D short axis Base view (cm) (Abbott)	LVOT VEL (m/s)	RVOT VEL (m/s)	E max (m/s)	
NORMAL	<1.5	<1.3	<1.2	<1.6	<1.3	<0.9	
PATIENT	NM	2.0	1.8	0.6	0.55	NM	

Adapted from June Boon, Veterinary Echocardiography, 1998
Abbott J & MacLean H JVIM 2006;20: 111-119, Moise et al. Am J Vet Res 47:1476, 1986. Pipers et al. Am J Vet Res 40:882, 1979.

INTERPRETATION OF THE FINDINGS & FURTHER RECOMMENDATIONS

Compared to the prior study, this reflects end-stage hypertrophic disease. The obstruction is no longer present, likely due to myocardial failure. The LV wall thicknesses are asymmetric and may suggest an infarcted region. Systolic function has developed and both atria are significantly dilated.

Given these findings, this certainly confirms the patient is now in congestive heart failure with evidence of both pleural and pericardial effusion. A thoracocentesis should be considered if the patient appears unstable. Certainly, continuing Lasix is warranted with addition of Pimobendan and Plavix. Finally, Atenolol is now contraindicated as the patient is bradycardic and systolic function depressed. Recommend wean as below.

The mean survival time for cats with CHF is 6-12 months, however most are able to maintain a good quality of life on medications (if pillled successfully). Patient will always remain at high risk for recurrent episodes of CHF and development of blood clots in the future. Monitoring of sleeping breathing rates at home is recommended as the best way to screen for recurrent CHF at home.

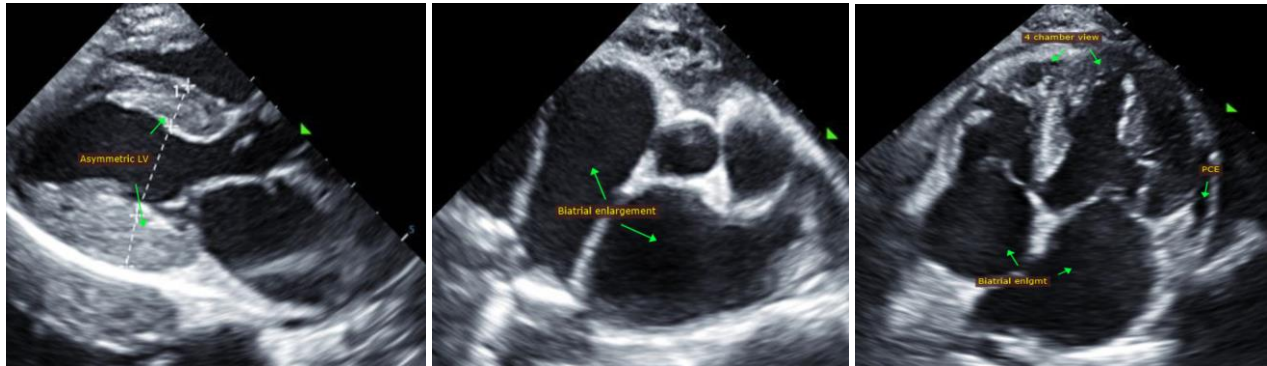
PLAN

Continue Lasix as prescribed. Institute blood thinner Clopidogrel (Plavix) 75mg tablets; give ¼ tab orally once daily (NOTE: this medication is very bitter on the cut edges; coat in entirety). Institute Pimobendan 1.25mg PO q12h. Consider thoracocentesis if warranted. Decrease Atenolol to ¼ tab q24h for 3-5 days, then discontinue.

Recommend recheck renal values and systemic blood pressure in 1-2 weeks, then every 3-4 months lifelong. If BP >130mmHG, institute ACE-I 0.5mg/kg PO q12h.

A recheck echocardiogram is recommended in 6 months to assess progression.

IMAGES



The information and recommendations provided are based on the images presented by the referring veterinarian. No evaluation can be communicated regarding pathology that was not visible in the image/video clips provided.

Thank you for this referral. This report was generated using transcription software, and minor dictation errors may be present. If the clinical or image interpretation does not parallel your findings or if I can be of any further assistance please contact me.

Maggie Machen Lamy, DVM
Diplomate of the American College of Veterinary Internal Medicine (Cardiology)
info@sonopath.com